


# VIÊM NÃO TỦY LAN TỎA CẤP


(Acute disseminated encephalomyelitis)



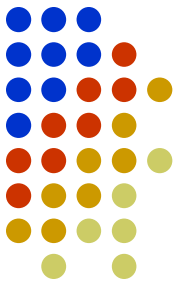
Dr. Trang Bao Doan  
Neurology Department



# Introduction

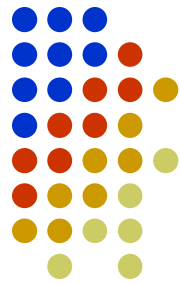


# ADEM

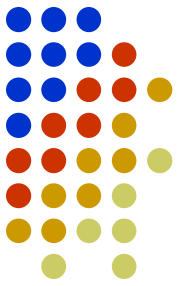


- Acute Disseminated Encephalomyelitis (ADEM) is a monophasic acute nonvasculitic inflammatory demyelinating disorder of the central nervous system characterized by diffuse neurologic signs and symptoms coupled with evidence of multifocal lesions of demyelination on neuroimaging.

# EPIDEMIOLOGY




- Post-infectious: viral or bacterial infection
- Postvaccinial: measles, mumps, rubella...
- Time: winter and spring



# PATHOGENESIS

- Incompletely understood autoimmune disorder of the central nervous system:
  - myelin autoantigens: Antiviral antibodies or a cell-mediated response to the pathogen cross react with the myelin autoantigens, resulting in ADEM (Epstein-Barr virus)...

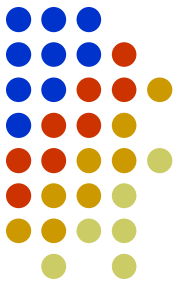


# CLINICAL FEATURES

- Systemic symptoms such as fever, headache, and fatigue often precede the development of neurologic deficits.
- Neurologic signs and symptoms: long tract signs (85%), acute hemiparesis(76%), cerebella ataxia (50%), cranial nerve palsies, spinal cord involvement, aphasia, seizures and visual dysfunction.


# Diagnostic criteria

(published by the International Pediatric Multiple Sclerosis Study Group, which proposed diagnostic criteria for ADEM in children)



1. A first clinical attack of central nervous system demyelinating disease with acute or subacute onset, polysymptomatic neurologic features, and encephalopathy
2. Brain MRI showing focal or multifocal lesions, predominantly involving the white matter, without evidence of previous white matter changes
3. Encephalopathy as a presenting symptom, with the onset of encephalopathy corresponding with the occurrence of the disease state (encephalopathy is defined to include behavioral changes, such as lethargy or irritability, or severe changes in the level of consciousness such as coma)

These features help distinguish ADEM from other clinically isolated syndromes, which have a greater risk for recurrence and subsequent diagnosis of MS.

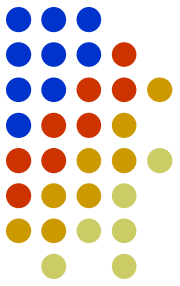


# Differential diagnosis

- Multiple sclerosis
- Optic neuritis
- Transverse myelitis
- Neuromyelitis optica (Devic disease)
- Other rare conditions




# Treatment

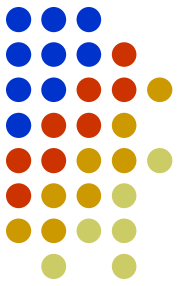


- Glucocorticoids (Grade 2C)
- Intravenous immune globulin (Grade 2C)
- Plasma exchange (Grade 2C)

# Role of Plasma Exchange

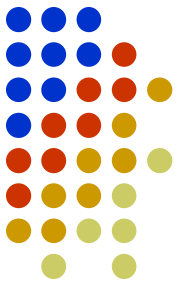


# Role of Plasma Exchange



- For patients with acute disseminated encephalomyelitis who fail to demonstrate clinical improvement by the third to fifth day of corticosteroid treatment, or children with life-threatening demyelination at onset, plasma exchange can be considered (Cortese et al 2011; Pohl and Tenenbaum 2012).

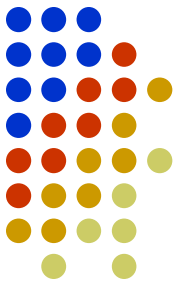
# Role of Plasma Exchange



Plasma Exchange (PLEX) is recommended if there is no response to corticosteroids. Intravenous immunoglobulin (IVIg) is recommended if there is no response to PLEX.

The strength of evidence for the recommendation of corticosteroids and PLEX are graded as moderate (p.4 ADEM of The Transverse Myelitis Association 2012).

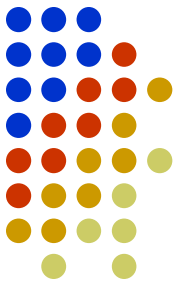
# Role of Plasma Exchange



- We suggest treatment with plasma exchange for children with ADEM who have longitudinally extensive transverse myelitis and who fail treatment with glucocorticoids and IVIG (Grade 2C).

(uptodate 2016)

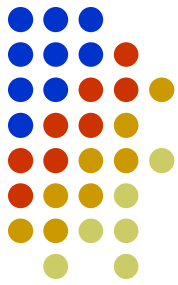
# Role of Plasma Exchange



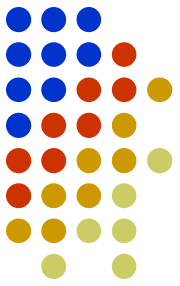
- six exchanges, one every other day, with each exchange consisting of 1 to 1.5 plasma volumes.

(uptodate2016)

# Benefits



- Removal of certain pathologic substances from the plasma will reduce further damage and may permit reversal of the pathologic process. The pathologic substance may be an autoantibody, immune complex, ...




# Complications

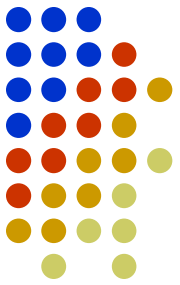
- Hypokalemia, hypocalcemia, coagulation factor depletion , immunoglobulin depletion, anaphylactic reactions, hives, transfusion-related acute lung injury (TRALI)



# Conclusion



# Conclusion



## ADEM


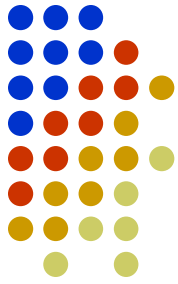
- Demyelinating disorder of the central nervous system
- Neurologic deficits and encephalopathy
- MRI: white matter lesions

## Treatment

- Glucocorticoids
- IVIG
- Plasma exchange

## Plasma exchange

- Fail treatment with glucocorticoids and IVIG (Grade 2C)
- Complication



Thanks  
for your attention!

Have a nice day 😊

